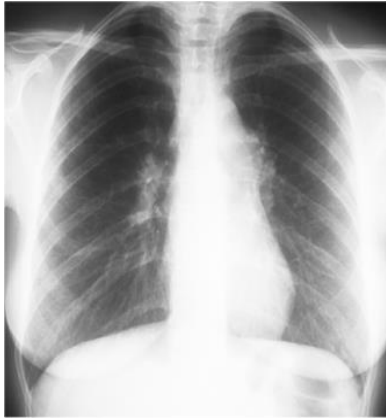

The many faces of sarcoidosis: Radiology

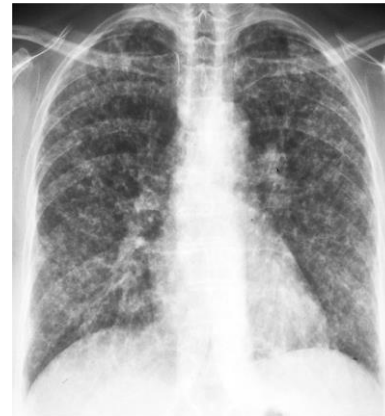

© WASOG: educational material

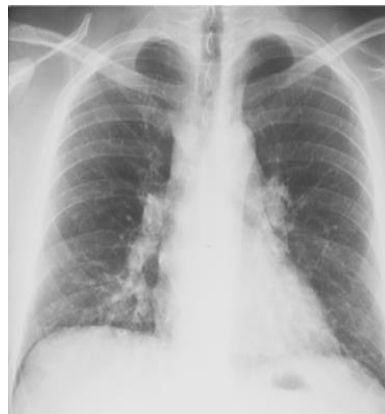Chest radiographic stages in sarcoidosis



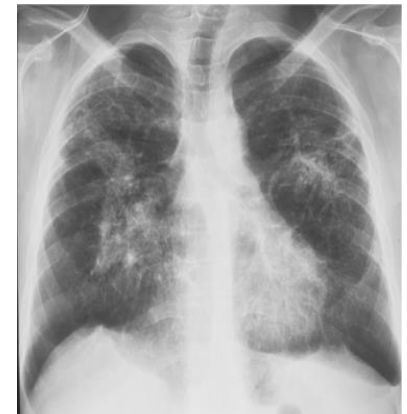stage I



stage III

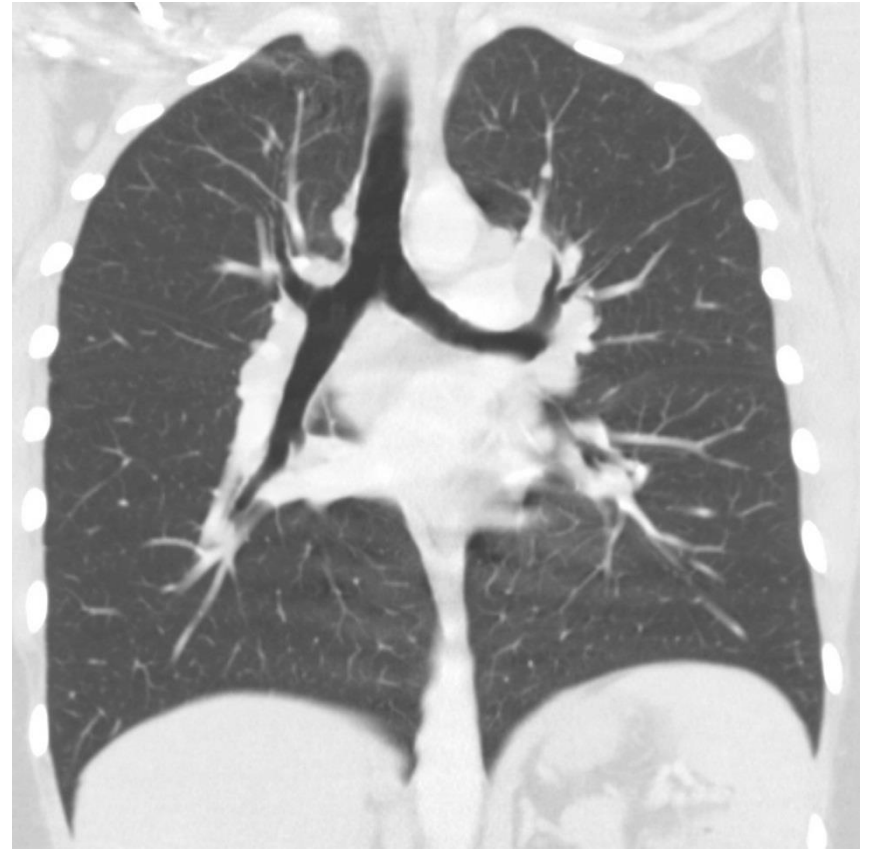
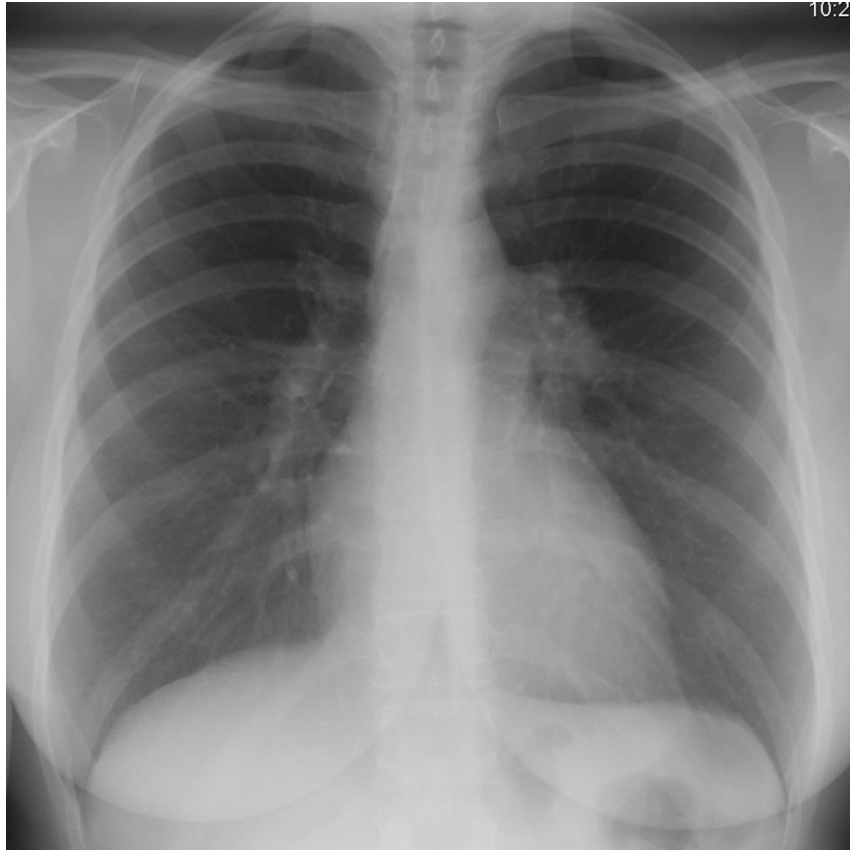


stage II

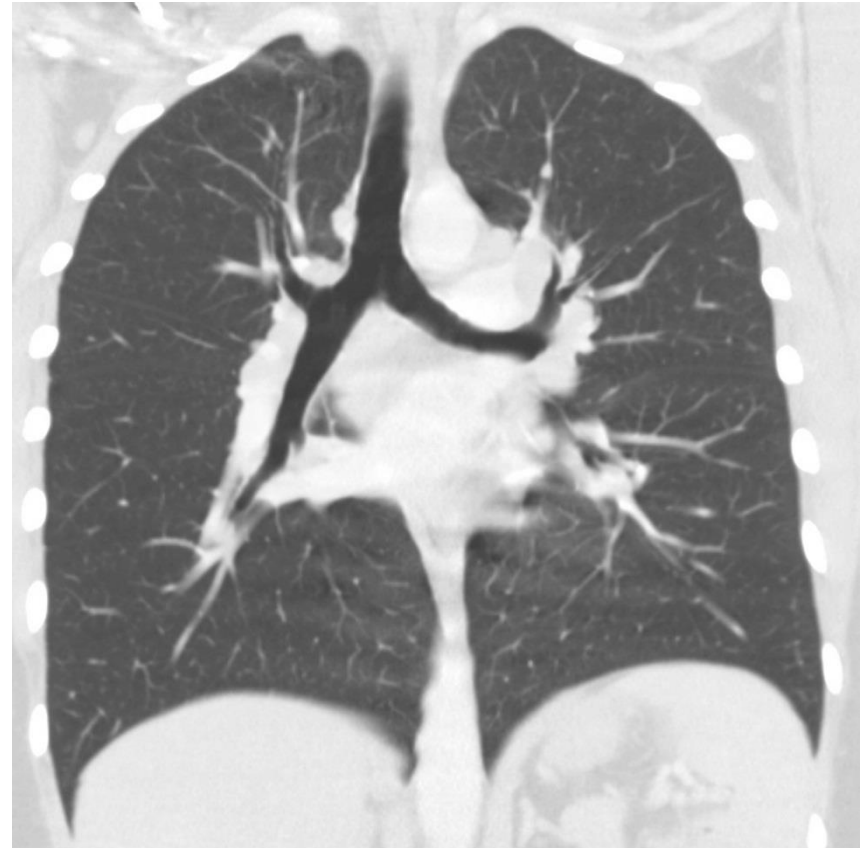
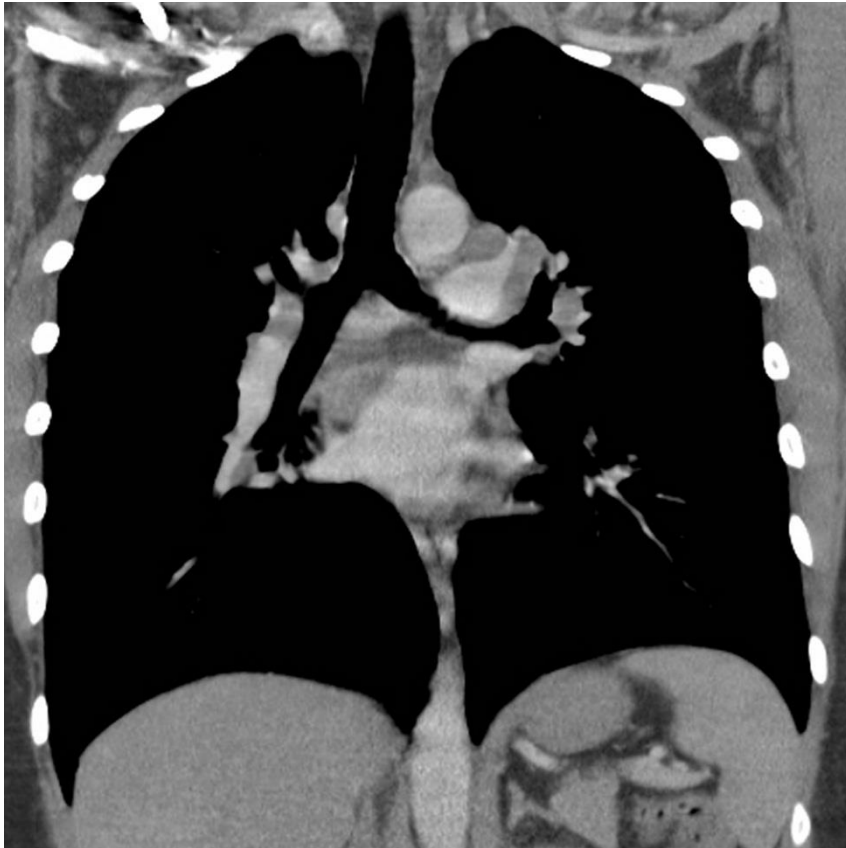


stage IV

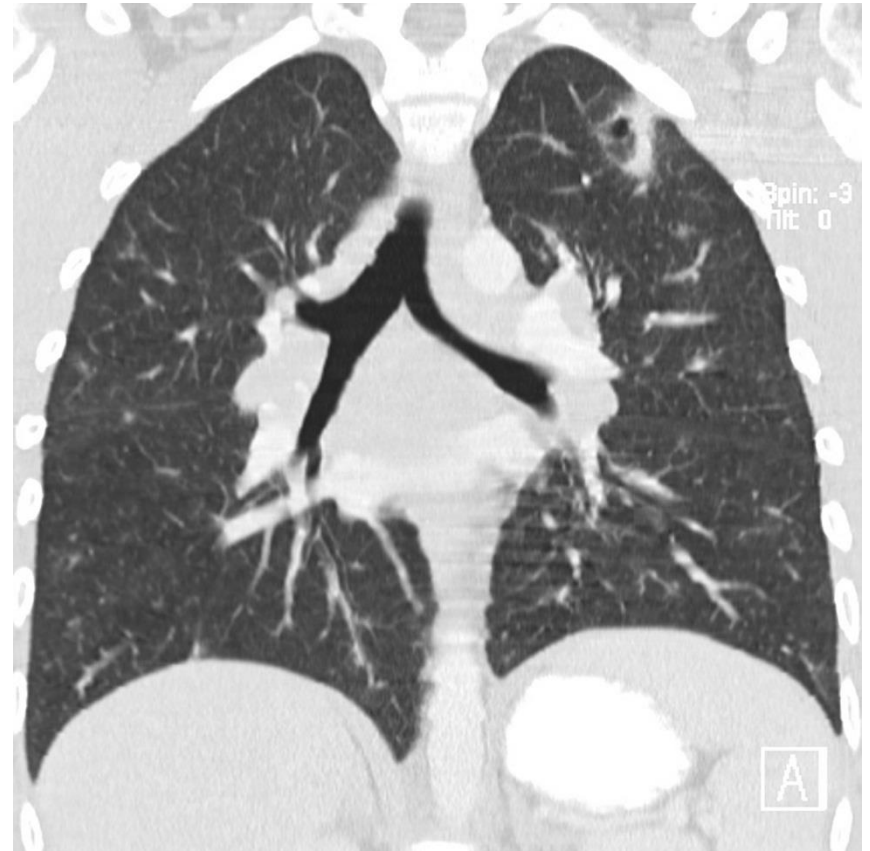
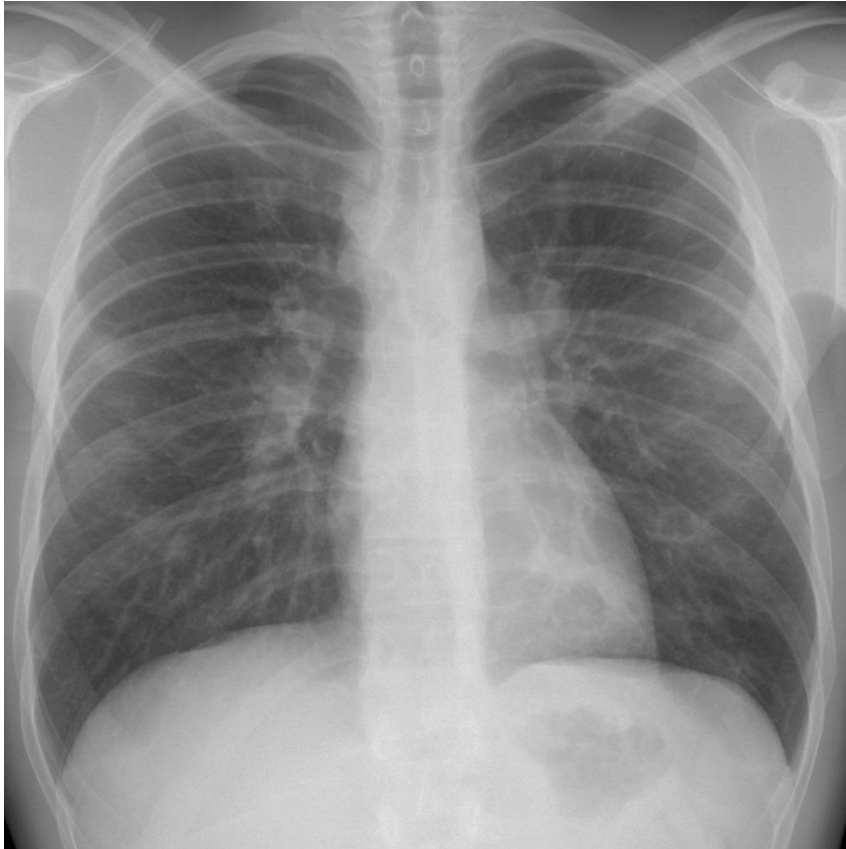
Sarcoidosis Chest X-ray stage I



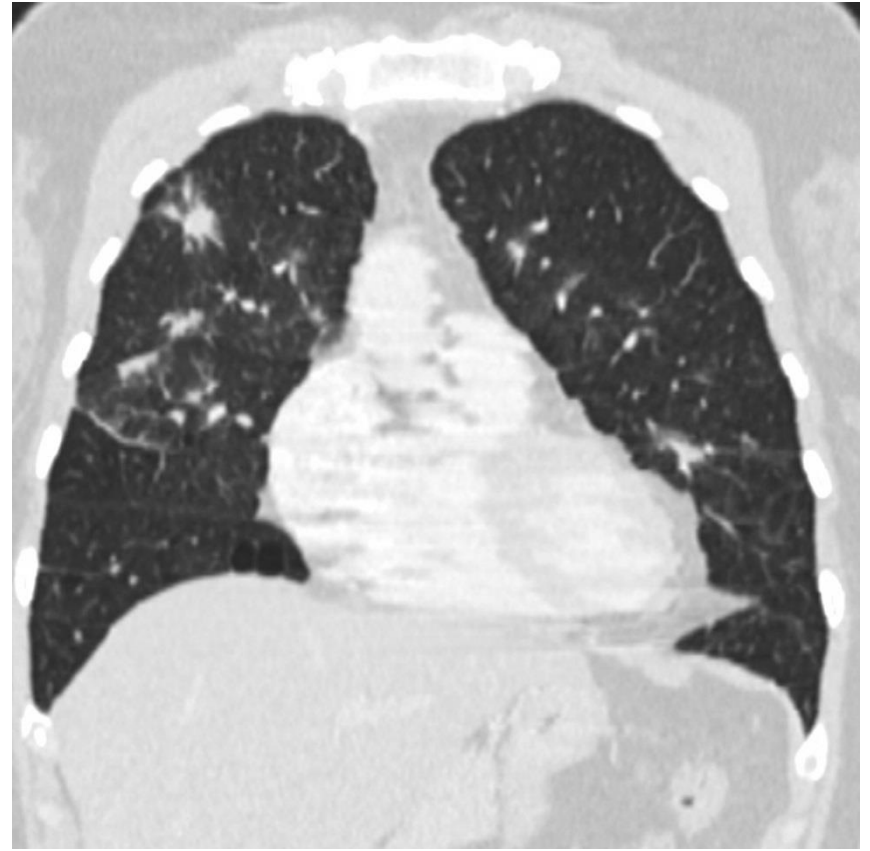
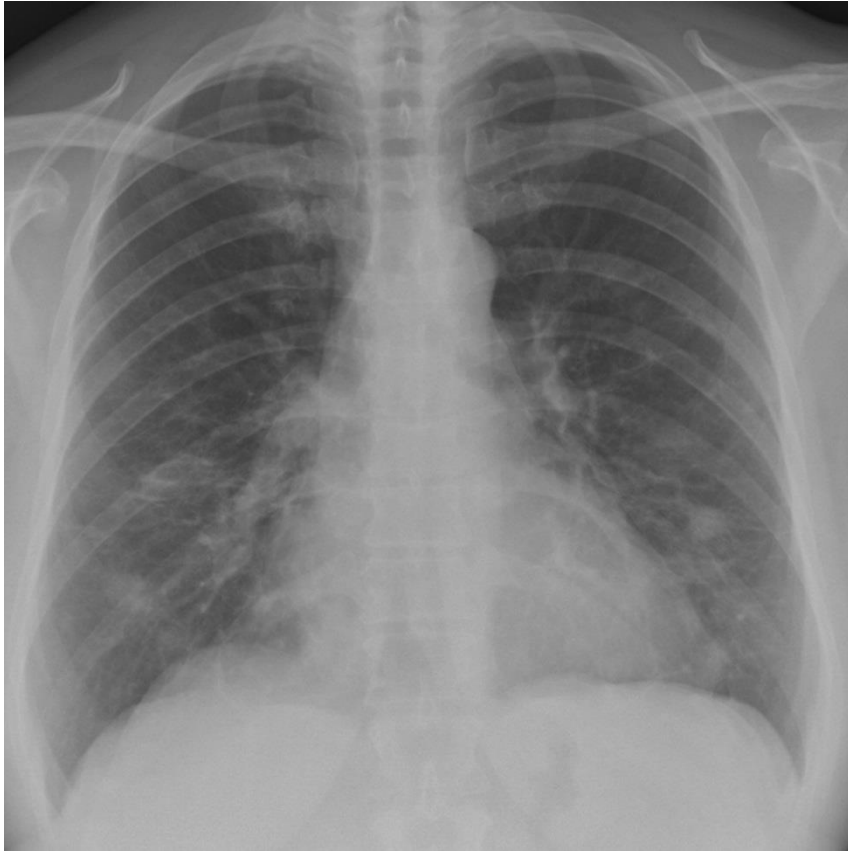
Sarcoidosis Chest X-ray stage I



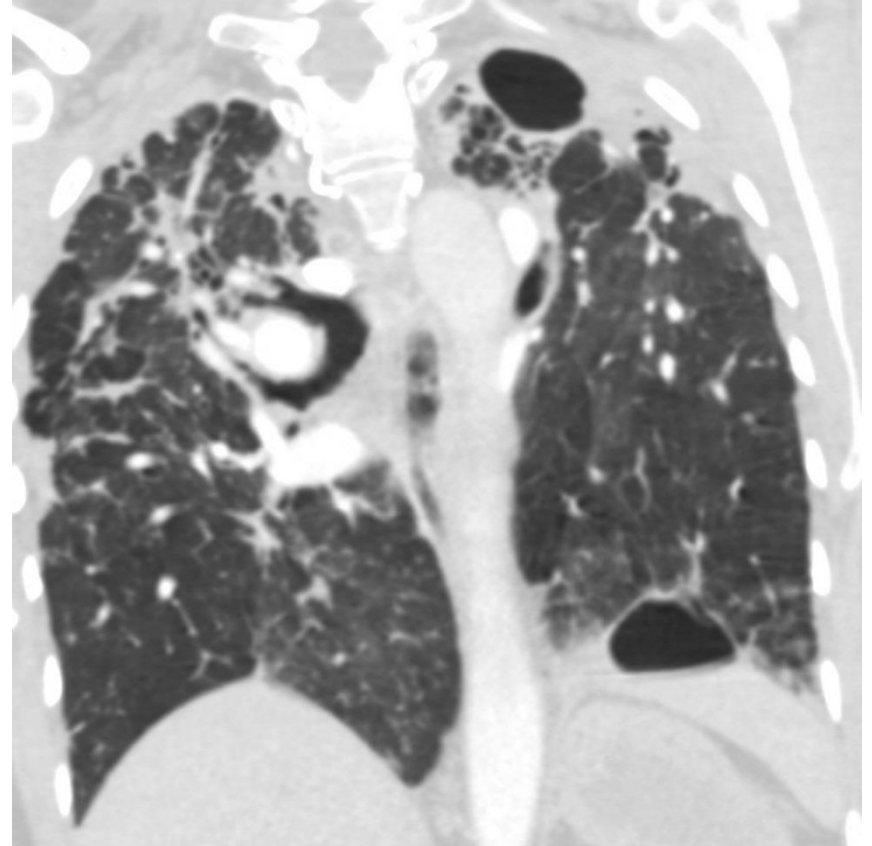
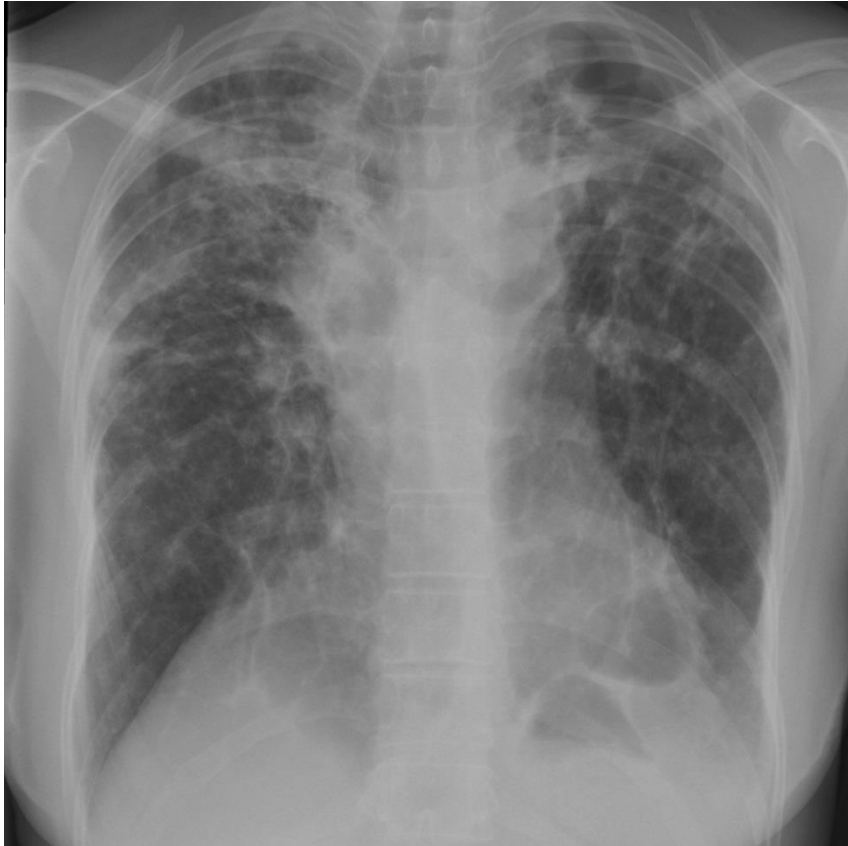Sarcoidosis Chest X-ray stage II



Sarcoidosis Chest X-ray stage III

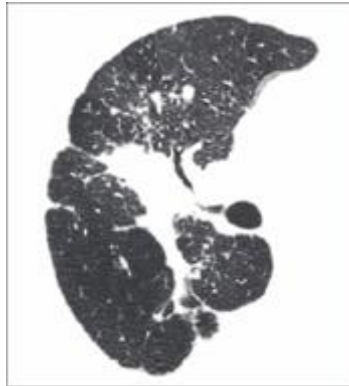


Sarcoidosis Chest X-ray stage IV

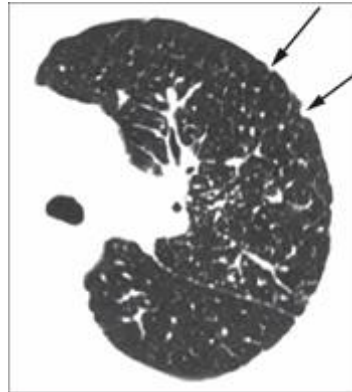

Visual HRCT score in sarcoidosis

adapted from Oberstein et al. (1997)



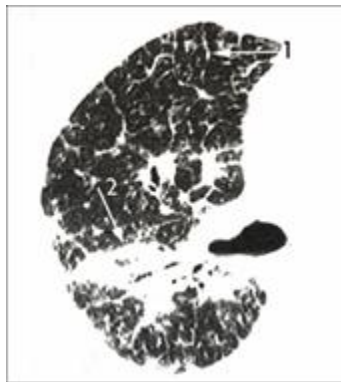
BVB: thickening or irregularity of the bronchovascular bundle



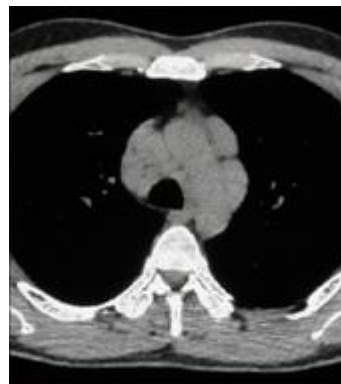PL: pleural thickening



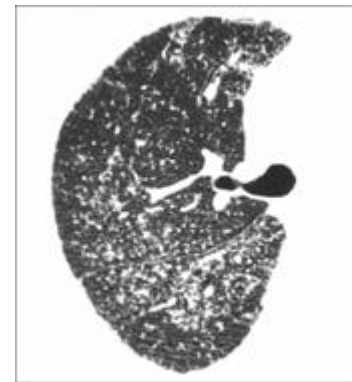
PC: parenchymal consolidations



1.LS: septal lines
2.BVB

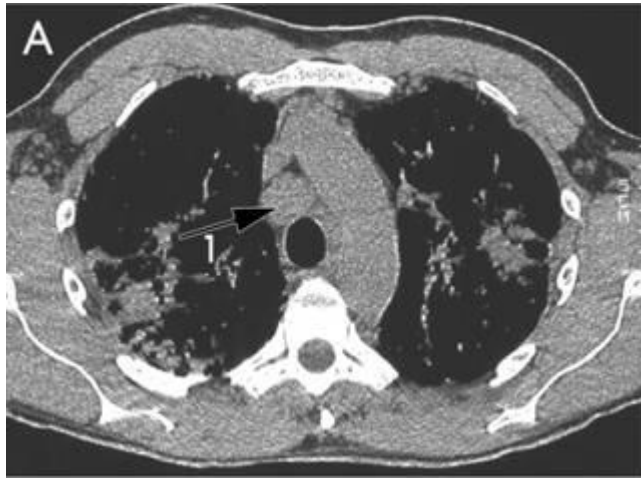

LN: lymph node enlargement

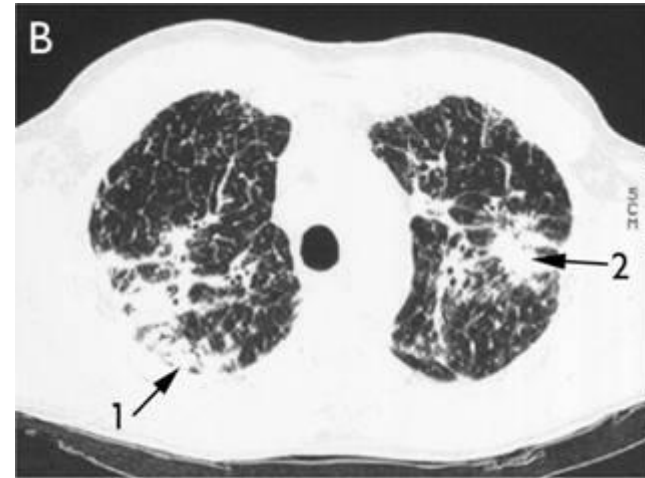


ND: intraparenchymal nodules

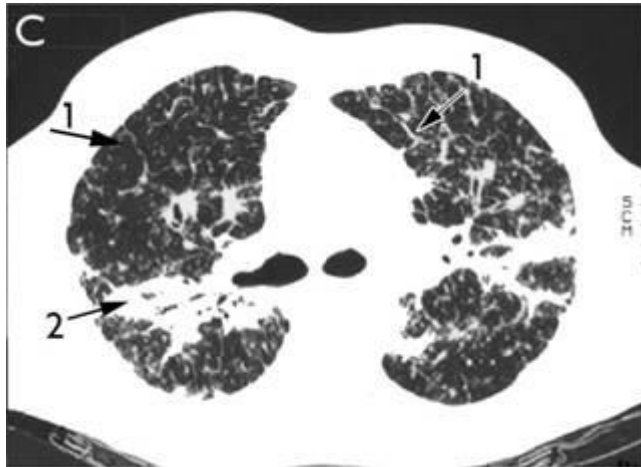
HRCT images of a sarcoidosis patient



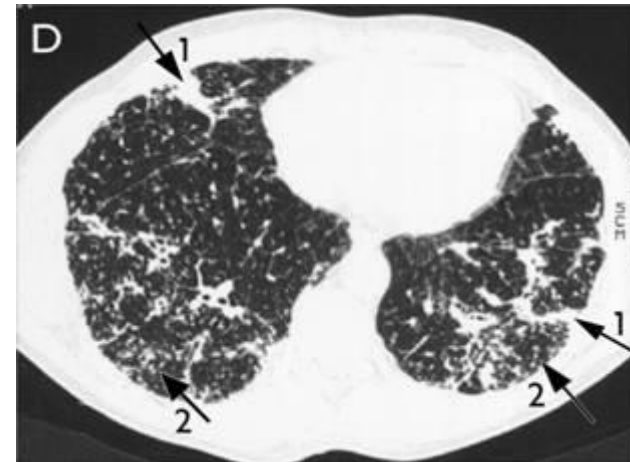
A: mediastinal setting; enlarged mediastinal lymph nodes, LN=3 (1→)



B: parenchymal consolidations, PC=1 (1→) thickening or irregularity of the bronchovascular bundle, BVB=2 (2→)



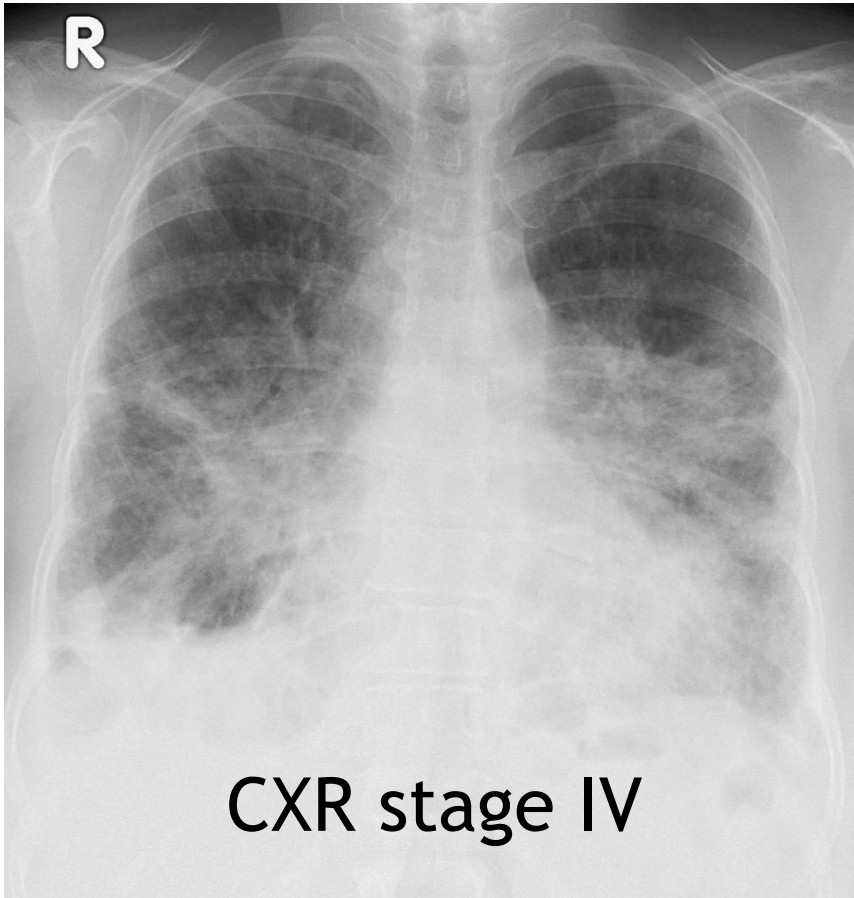
C: septal lines, LS=2 (1→) BVB=2 (2→)



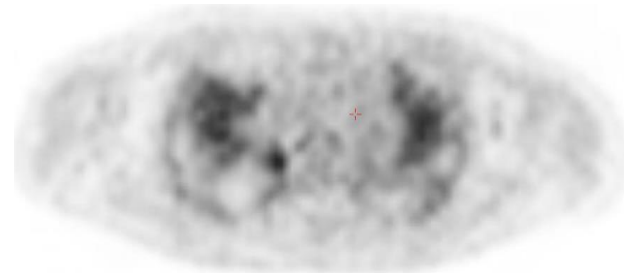
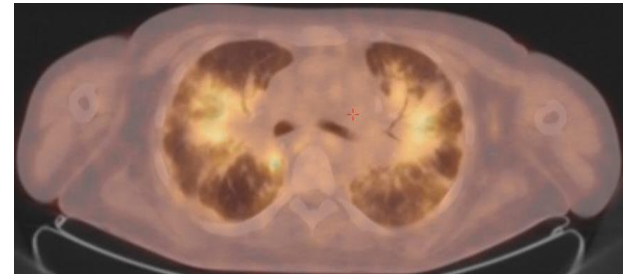
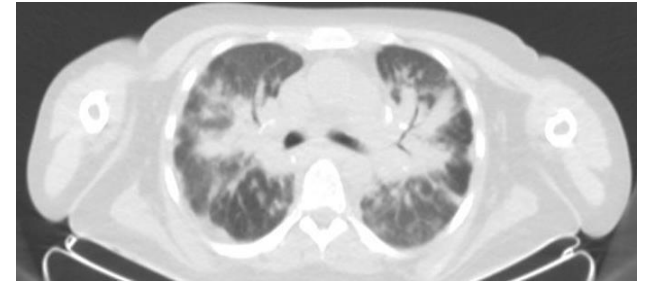
D: focal pleural thickening, PL=1 (1→), intraparenchymal nodules, ND=2 (2→) © WASOG

Sarcoidosis patient with inflammation

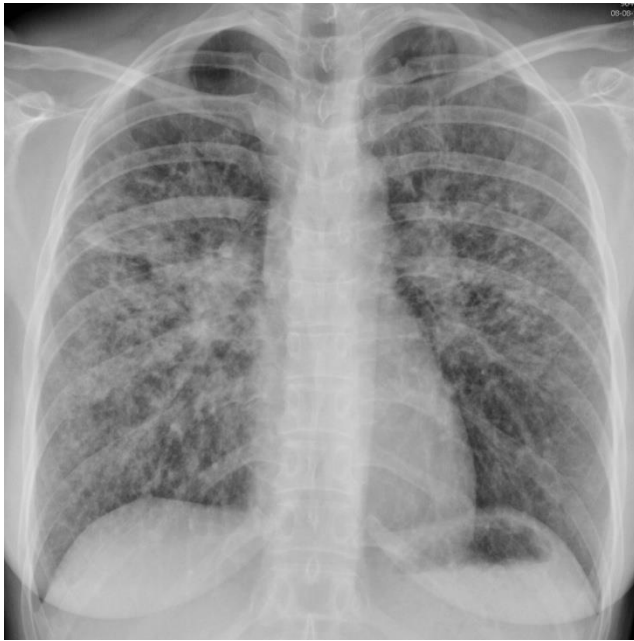Chest X-ray



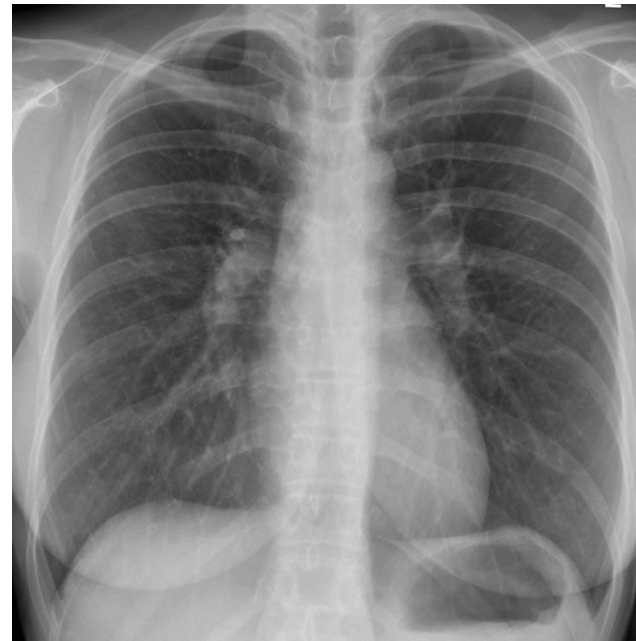PET/CT



Case: 38-year-old woman



before MTX



after MTX

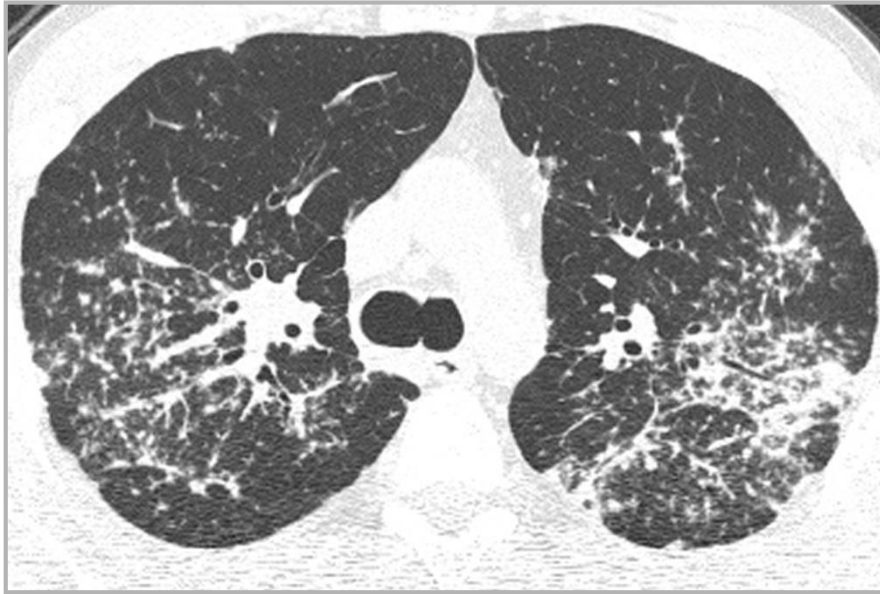Treatment

MTX 12.5 mg once a week subcutaneous

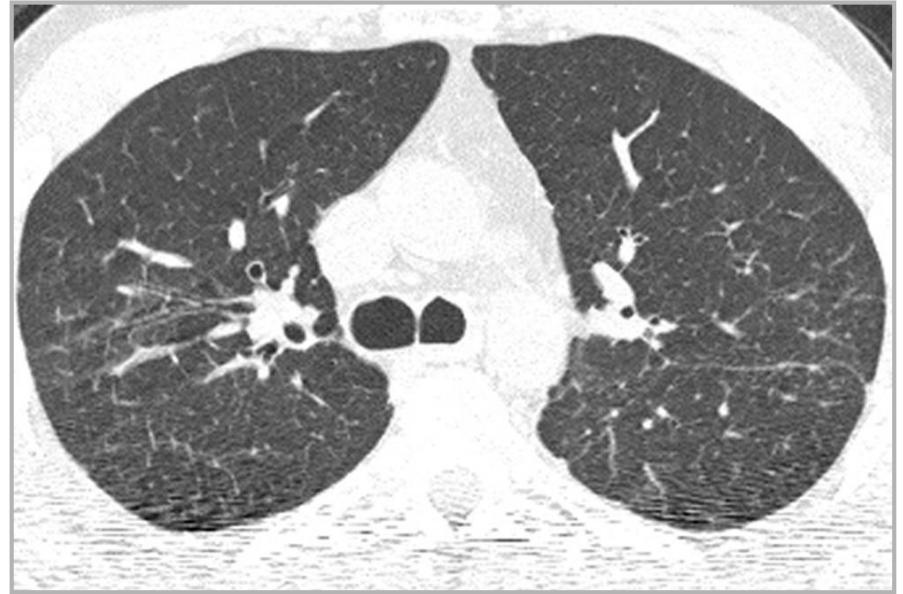folic acid 5 mg twice a week

prednisone 7.5 mg daily orally

Case: 36-year-old man



HRCT before MTX



HRCT after 6 months MTX

Treatment

MTX 12.5 mg once a week orally

Folic acid 5 mg once a week

Prednisone 10 mg daily

WASOG

Join us: become a member!

World
Association for
Sarcoidosis and
Other
Granulomatous Disorders



www.wasog.org