

Re-occurrence of bilateral sarcoid pleural effusions: a rare presentation

Tanmay Jain
Rahul kumar Sharma
Deepak Talwar
Rajat Saxena
Charul Dabral

Corresponding author: Dr. Rahul Kumar Sharma
Metro Centre for Respiratory Diseases, Metro Multispecialty Hospital,
Sector 11, Noida, UP, India
email: dr.rahulksharma@gmail.com

INTRODUCTION

Pleural involvement is quite uncommon in sarcoidosis. Development of bilateral reoccurring sarcoid pleural effusions is unreported, being extremely rare, and many other common causes need to be excluded before concluding it to be due to sarcoidosis.

Here we report a case of 63 year old male patient who presented with bilateral reoccurring pleural effusion. Repeated pleural fluid tests as well as was many other investigations were inconclusive. Empiric anti tubercular treatment too had no effect and effusions remained undiagnosed for more than one year.

VATS biopsy of lung, pleura and lymph nodes led to establishment of diagnosis of sarcoid pleural effusions with excellent therapeutic response to oral corticosteroids.

MEDICAL HISTORY AND TESTS

Initial visit - 19th March 2018

- 63 years Male , Never smoker , Hypertensive for last 15 years
- No occupational or environmental exposure

Clinical data:

Presented with complaints of shortness of breath and left sided dull aching chest pain on and off since 2 years. Patient was evaluated outside, and found to have bilateral exudative, lymphocytic, ADA negative (18.6 U/L) pleural effusion with bilateral lung infiltrates on chest x-ray in 2016.

CECT chest revealed diffuse ground glass opacities with multiple nodular infiltrates in bilateral lower lobes and sub-pleural nodules with bilateral pleural effusion.

Anti tubercular therapy (HRZE) with short course steroids(1 month) was started empirically by local physician and continued for 5 months but stopped in view of no relief. Patient was referred to our center for further evaluation

The patient had persistent symptoms since then which increased in severity since last 3 months along with significant weight loss (5kg). There was no associated history of fever, cough, hemoptysis, orthopnea, joint pains or any skin lesions.

MEDICAL HISTORY AND TESTS

Clinical data:

- Physical Examination: At admission, patient was afebrile, tachycardic and breathless (pulse rate 102/minute, respiratory rate 24/minute) with oxygen saturation of 94% on room air.
- There was no pallor, cyanosis, lymphadenopathy, pedal edema or skin lesions on general physical examination.
- Respiratory system examination revealed non shifting dullness in bilateral lung bases with decreased breath sounds.
- Auscultation: Breath sounds were diminished in bilateral infra-scapular and infra-axillary areas.
- There was no added sounds
- Rest of systemic examination was within normal limits.

IMAGING (CHEST X-RAY)

Chest Xray- (A) Blunting of bilateral costophrenic angles with bilateral nodular shadows in middle and lower lobes. CXR (B) showed partial improvement but CXR (C) showed reoccurrence of same findings as seen in earlier CXR (A)

The findings were suggestive of bilateral reoccurring pleural effusion with lung infiltrates. Partial improvement in middle CXR could be attributed to ATT + steroids but pleural effusions and lung infiltrates persisted despite ATT.

→ Conclusion: Chronic reoccurring bilateral Exudative pleural effusions (Cause ?)

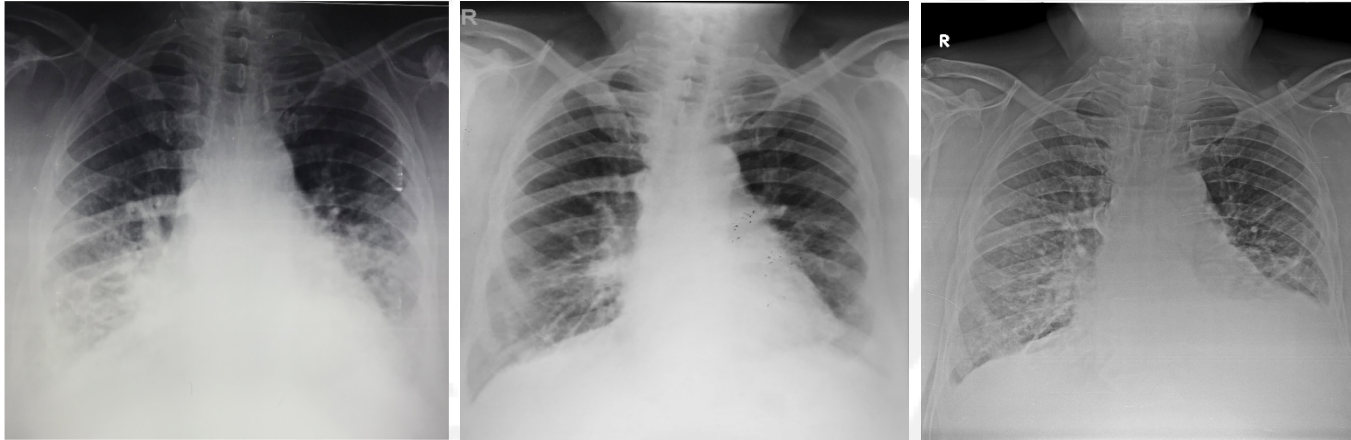


Figure 1 A (8th June 2016), 1B (11th Feb 2017), 1C (19th March 2018)

Imaging (HRCT)

22nd March 2018:

HRCT Chest findings revealed bilateral pleural effusion (left more than right) with bilateral randomly distributed lung nodules involving fissure and sub pleural areas of variable sizes. Few calcified lymph nodes were seen in the mediastinum (sub carina and hilar)

Conclusion: Differentials include lymphoma/ metastatic malignancy

IMAGING (PET-CT)

Figure 2a- pulmonary nodules at lower lobes

Figure 2b - Bilateral pleural effusion

Figure 2c –Upper lobes relatively spared with no nodules

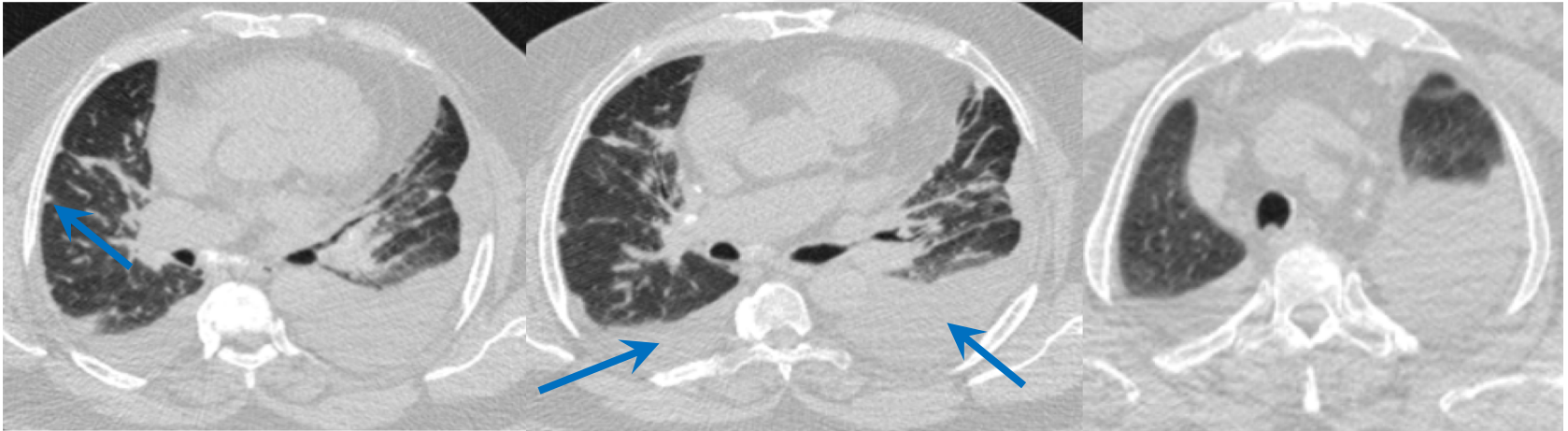


Figure 2a

Figure 2b

Figure 2c

IMAGING (PET CT)

26th April 2018

PET CT findings-

FDG avid (SUV max-3.4) ill defined nodular opacities seen in both lung parenchyma.

Non FDG avid multiple calcified lymph nodes seen in paratracheal, prevascular, pre/subcarinal, and bilateral hilar regions with largest of size 19x13mm.

Findings are suggestive of Bilateral active parenchymal lung disease with bilateral effusions

No extra pulmonary FDG avid lesion was seen

A filling defect in main PA - need to r/o PTE

Advise :

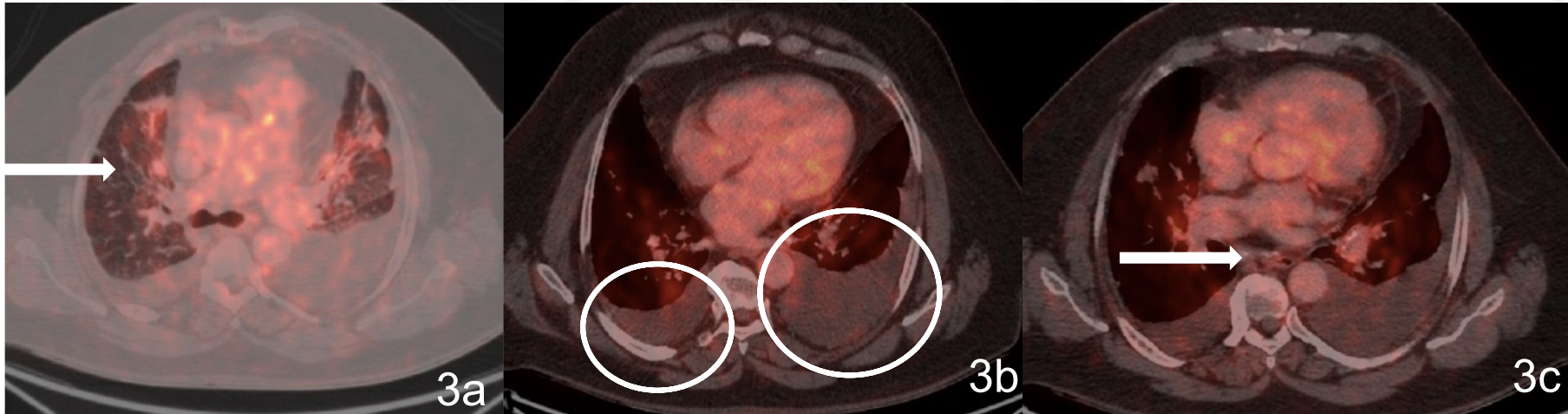
CT – PA angiography

IMAGING (PET-CT)

Figure 3a- PET avid ill defined nodular opacities in bilateral lung parenchyma

Figure 3b - Bilateral pleural effusion (circles)

Figure 3c –Multiple calcified lymph nodes



CT Pulmonary Artery Angiography

Figure 4 CTPA showing No filling defect

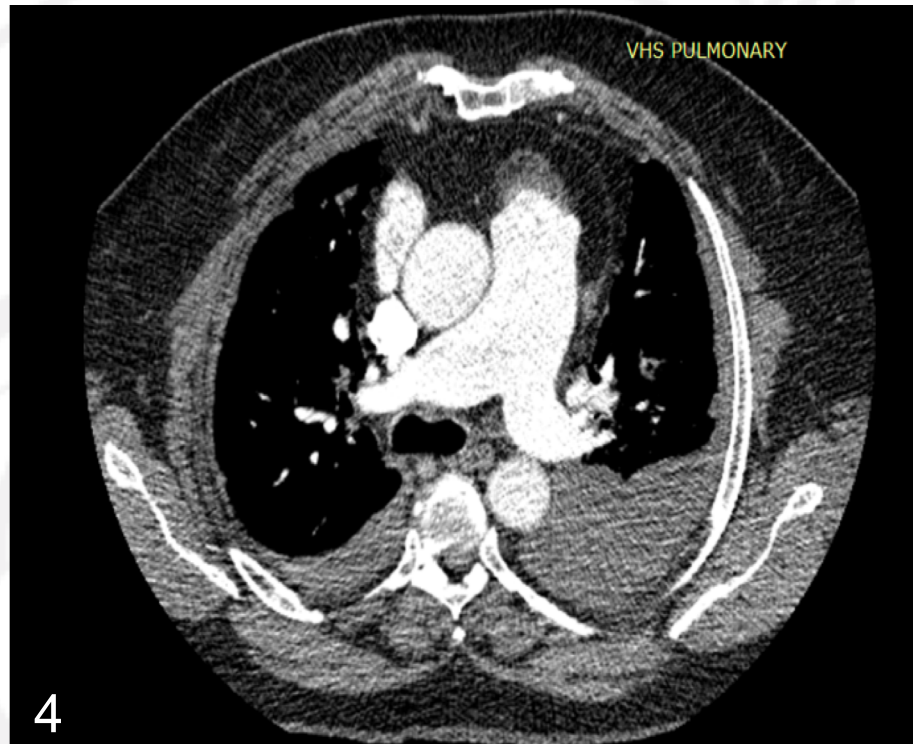


Figure 4

LUNG FUNCTION TESTS

(27th April 2018)

Forced expiration measurements:

- FEV1 / FVC % - 81.14
- FEV1 L (%) -1.42 (48%) predicted
- FVC L(%) -1.77 (47%) predicted
- RV L/% predicted 1.61(67%) predicted
- TLC L (%) 3.31L (51%)predicted
- DLCO (ml/mm*Hg) 13.71 (53%) predicted
- KCO(ml/mim*mmHg*L) 5.74 (145%) predicted

Pulmonary function tests were suggestive of ventilatory restriction with reduced diffusion capacity

LABORATORY

2nd April 2018- No abnormality

Test	Results
LDH	164 U/L
Immunology	Not done
ACE	54 nmol/ml/min
Serum precipitins	Not done
Haematology	HB 16 gm% TLC 6500 cu mm ³
Biochemistry	Serum(s) bilirubin 0.6mg/dl, SGOT(AST) 30.0U/L; SGPT(ALT) 35.0U/L. S. proteins 7.32mg/dl; S. albumin 3.68mg/dl S.Calcium: 9.4mg/dl Urine 24 hours calcium: 321mg/dl NT-proBNP: 19 pg/ml
Metabolic assessment	Ph-7.37, P _{CO} ₂ -50, PO ₂ -66, HCO ₃ -28.90 O ₂ Sat- 94% on Room air
Autoantibodies	ANA by ELISA and Immunofluorescent & Extractable nuclear antigen was negative including Myositis Panel
Precipitating antibodies	Not done

LABORATORY

Pleural fluid analysis (2nd April 2018)

	PLEURAL FLUID
SUGAR (mg/dl)	122
PROTEIN (gm/dl)	5.30
ADA (U/L)	10.60
TLC (/mm ³)	2000
DLC	L98%N2%
NT pro BNP(pg/dl)	58
Triglycerides(mg/dl)	38

Conclusion: lymphocytic exudative ADA negative effusion

BRONCHOSCOPY

27th April 2018

- On Macroscopic assessment, no endobronchial lesion seen.
- Bronchial aspirate showed clear fluid with no malignant cells; AFB and GenXpert negative
- BAL differential cell count:

	BAL differential cell count
Alveolar macrophages	62%
Neutrophils	15%
Lymphocytes	13%
Eosinophils	0%

Conclusion: Within normal limits (Lymphocytes are mildly elevated)

BIOPSY

(8th May 2018)

- Type of biopsy:
 - VATS pleural, Lymph node and lung Biopsy
- Which lungs and what sections?
 - Left lung- upper lobe anterior segment and lower lobe lateral segment
- Why was it decided to do a biopsy?
 - In view of undiagnosed pleural fluid report with persistent and reoccurring pleural effusions and multiple nodules in the lung, a single procedure likely to have highest yield was chosen

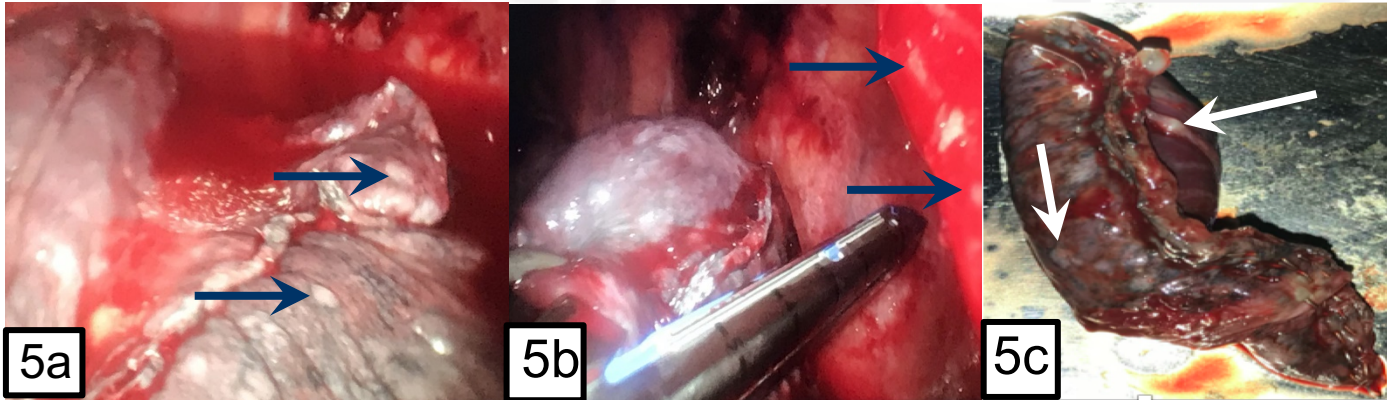
PATHOLOGY (IMAGES)

Gross findings

Figure 5a: VATS picture showing nodules on visceral pleura

Figure 5b : VATS picture showing nodules on parietal pleura

Figure 5c : Lung specimen showing multiple nodules



PATHOLOGY

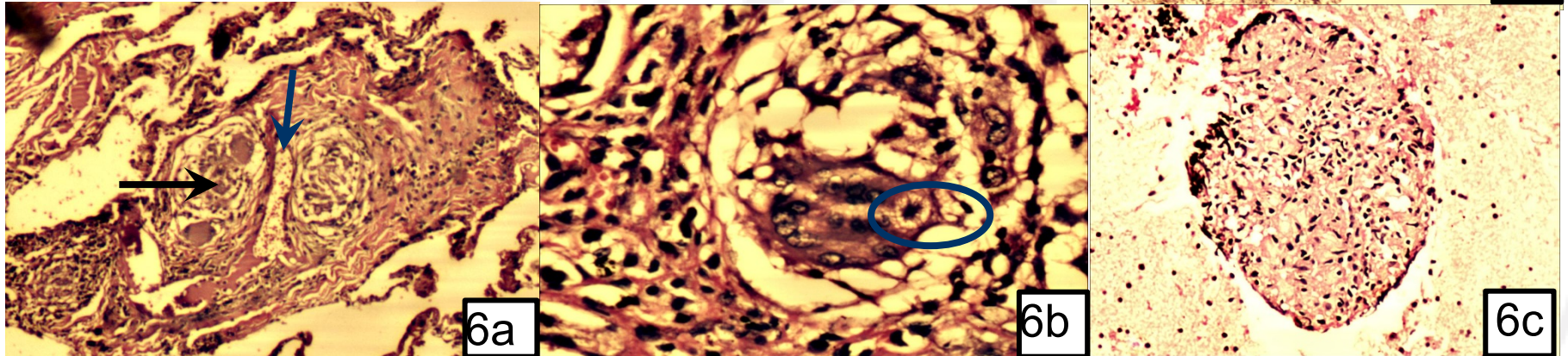
Summary of pathologic findings (11th May 2018)

- Patterns detected in the following tissues :
 - Lung Biopsy: Noncaseating compact epithelioid cell granuloma with foreign body and multinucleate giant cells and asteroid bodies seen;
 - Pleural Biopsy: Non caseating epithelioid granulomas; AFB and Gen Xpert negative
 - Lymph nodes : Non caseating granuloma, Negative for infections
 - All Tissues were screened for infections :
 - AFB and Gen Xpert negative
 - PAS stains negative for fungus
 - Immunohistochemistry was negative for malignancy
 - Patterns not detected? No necrosis, no honeycombing, no malignant cells
- Conclusion: Granulomatous inflammation with no necrosis suggestive of sarcoidosis

PATHOLOGY (IMAGES)

Figure 6: Lung biopsy

- a) Non caseating epithelioid cell granuloma (black arrow) and vessel (blue arrow)
- b) Asteroid body
- c) Lymph node biopsy showing non caseating granuloma
- d) Pleural biopsy showing non caseating epithelioid granulomas



Histopathology of Lung biopsy 6(a) showing compact granuloma(black arrow) adjacent to vessels(blue arrow) Scanner view 10X & 6(b)40X showing asteroid body 6(b) 6c)Histopathology of lymph node biopsy showing compact granuloma 10x. 6(d) histopathology of pleural biopsy showing multiple compact granuloma 4X

MDD DIAGNOSIS

(11th May 2018)

Clinical : Need to consider malignancy

Radiology: Bilateral pleural effusion with parenchymal nodules

Pathology: Sarcoidosis

Differential diagnosis?

- Tuberculosis
- Malignancy
- Sarcoidosis

In MDD it was concluded that it's a case of Pulmonary Sarcoidosis with sarcoid related bilateral pleural effusions

EXPERT OPINION

Treatment and Discussion:

Treatment: Patient started on oral steroids (Prednisolone 0.5mg/kg/day) and showed partial symptomatic improvement within 2 weeks of therapy with marked clearing at 4 weeks (figure 7)

Discussion: Pleural effusion in sarcoidosis due to pleural localization of lung parenchymal granulomas or blockage of lymphatics can occur but is rare (0.7-10% on chest x rays)¹⁻⁶. Most reported cases are unilateral, small and self limiting. Presence of clinically significant bilateral pleural effusions is unusual in sarcoidosis. Other common differentials like tuberculosis, heart failure, malignancy and autoimmune diseases, chylothorax etc. need to be ruled out before making a diagnosis of sarcoid related pleural effusion. Pleural fluid ADA may be misleading.

A definitive diagnosis of sarcoid pleural effusion relies on a pleural biopsy demonstrating non-necrotizing granulomas along with histopathological involvement of other organs like lung parenchyma.⁷ Asteroid bodies are stellate inclusions with numerous rays radiating from a central core. Although these inclusions are non-pathognomonic for sarcoidosis, these may help in clinching the diagnosis.

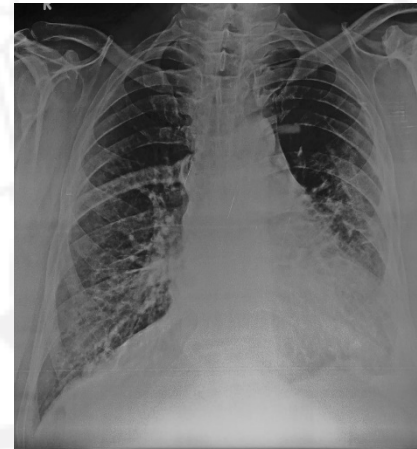


Figure 7: x-ray showing response after therapy

EXPERT OPINION

Treatment and Discussion:

A study reported only 1.1% of 181 sarcoid patients seen at a university hospital to have sarcoid related pleural effusion on biopsy and right sided effusions were more common.⁸ Bilateral effusions have been not reported so far. Presence of involvement of extra pulmonary site is more likely to provide confident diagnosis of sarcoidosis as it's a systemic disease. However, isolated organ sarcoidosis is more commonly reported with brain or heart involvement.

Our case though had involvement of pleura (both visceral as well as parietal), lung parenchyma and mediastinal nodes demonstrated by classical non caseating granulomas still had only intra thoracic involvement. Tuberculosis being one main mimicker in our country in such situations was ruled out by mycobacterial testing in all pathology and fluid samples, no response to empiric ATT for 5 months as well as absence of any constitutional features in this case. Also, PET-CT scans showed no other organ involvement that could be biopsied.

Diagnosis of pleural effusion in a known case of sarcoidosis would need to rule out infections, malignancy and heart failure, while confirming pleural effusion as a presenting feature of sarcoidosis is far more difficult.

EXPERT OPINION

Treatment and Response :

Asymptomatic pleural effusions may resolve with wait and watch policy and spontaneously resolving within 6 months.

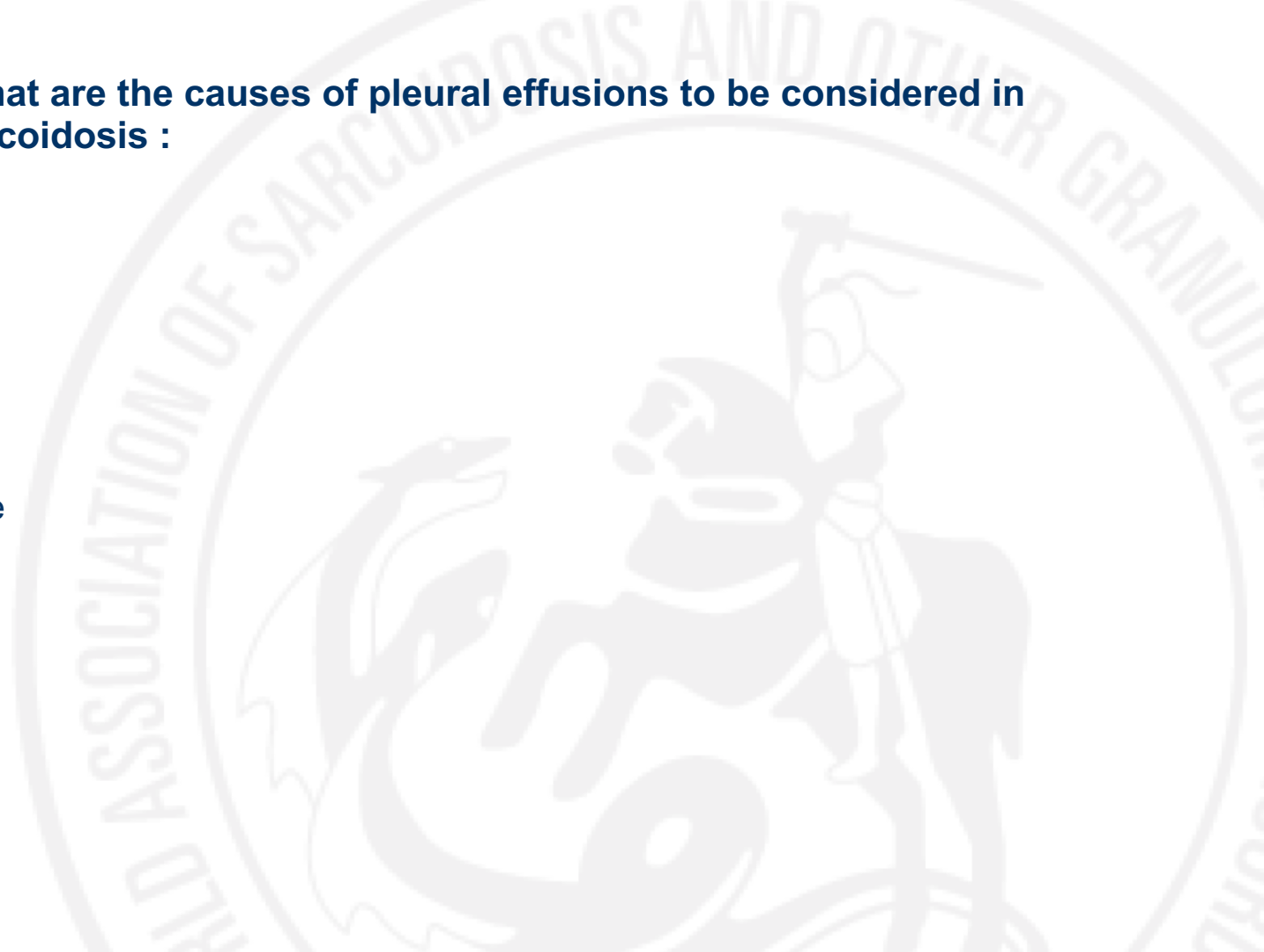
Recurrent, symptomatic pleural effusions for longer periods or with deteriorating lung functions, warrant considerations for therapy.

Case reports of treatment of sarcoid related pleural effusions with oral steroids leading to complete resolution has been reported earlier too but was unilateral and with acute presentation.⁹

Pleural scarring's may be left after spontaneous resolution of sarcoid related pleural effusions but with steroids no such permanent changes have been reported.

QUESTION 1 What are the causes of pleural effusions to be considered in patients with sarcoidosis :

1. Tuberculosis
2. Heart failure
3. Chylothorax
4. Malignancy
5. All of the above



Q 1 : Correct answer: 5

Explanation:

- Pleural effusion is an uncommon finding in sarcoidosis due to blockage of lymphatics.¹ Alternative and common diagnosis like congestive heart failure , tuberculosis (specially in endemic countries),malignancy and chylothorax (in recurrent effusions) must always be ruled out before labelling the effusion due to sarcoid¹. Chylothorax can also be a associated with presenting features of sarcoidosis.^{11,12}

QUESTION 2 How to establish the diagnosis of sarcoid related pleural effusion in a patient presenting first time with pleural effusion:

1. Pleural fluid analysis showing lymphocytic, exudative and ADA not elevated effusion
2. Biopsy of pleura with HPE showing non-caseating granulomas
3. Biopsy of at least two different sites demonstrating NS granulomas e.g lung & pleura
4. Since pleural effusion is an unusual clinical presentation, 2nd site of biopsy from extra pulmonary site would make confident diagnosis of sarcoidosis

- Correct answer: 4

- EXPLAIN :

Q 2 : Correct answer: 4

Explanation:

Please explain the answer, provide literature if feasible.

- Sarcoid pleural effusion are reported as exudate with lymphocytic predominance by light criteria⁶. but they can be protein discordant with normal or near normal LDH ratio. So pleural fluid analysis is not considered to be diagnostic in sarcoid effusion¹³.
- Definitive diagnosis pleural effusion due to sarcoidosis requires a pleural biopsy showing non necrotizing granuloma. And as per definition at least two site biopsy is required to make the confident diagnosis of sarcoidosis.

LEARNINGS FROM THE CASE

The most important take home messages of the case are:

- 1) Bilateral reoccurring pleural effusions is an unusual and uncommon presentation of sarcoidosis
- 2) Histopathological diagnosis would require tissue to demonstrate granulomas with no alternative causes of sarcoid like granulomatous diseases.
- 3) Extra pulmonary site if involved can be sampled to demonstrate granulomatous pathology along with granulomas in pleura; this would secure a more confident diagnosis.
- 4) Long term follow up is required as the course of disease as well as future development may clarify the final diagnosis.

References

1. Chusid EL, Siltzbach LE. Sarcoidosis of the pleura. *Ann Intern Med* 1974; 81(2): 190–4.
2. Sharma OP, Gordonson J. Pleural effusion in sarcoidosis: a report of six cases. *Thorax* 1975; 30(1): 95–101.
3. Beekman JF, Zimmet SM, Chun BK, Miranda AA, Katz S. Spectrum of pleural involvement in sarcoidosis. *Arch Intern Med* 1976; 136(3): 323–30.
4. Wilen SB, Rabinowitz JG, Ulreich S, Lyons HA. Pleural involvement in sarcoidosis. *Am J Med* 1974; 57(2): 200–9.
5. Tommasini A, Di Vittorio G, Facchinetti F, et al. Pleural effusion in sarcoidosis: a case report. *Sarcoidosis* 1994; 11(2): 138–40.
6. Soskel NT, Sharma OP. Pleural involvement in sarcoidosis. *Curr Opin Pulm Med* 2000; 6(5): 455–68.

7. Hunninghake GW, Costabel U, Ando M, Baughman R, Cordier JF, du Bois R, et al. ATS/ERS/WASOG statement on sarcoidosis. American Thoracic Society/European Respiratory Society/World Association of Sarcoidosis and other Granulomatous Disorders. *Sarcoidosis Vasc Diffuse Lung Dis* 1999;16: 149–73.
8. Huggins JT, Doelken P, Sahn SA, King L, Judson MA. Pleural effusions in a series of 181 outpatients with sarcoidosis. *Chest* 2006; 129(6): 1599–604.
9. Joshi S, Periwal P, Dogra V, Talwar D. Sarcoidosis as unusual cause of massive pleural effusion. *Respir Med Case Rep* 2015 Oct 13; 16:143–5.
10. Jarman PR, Whyte MK, Sabroe I, Hughes JM. Sarcoidosis presenting with chylothorax. *Thorax*. 1995; 50(12):1 324–5.
11. Lengyel RJ, Shanley DJ. Recurrent chylothorax associated with sarcoidosis. *Hawaii Med J* 1995; 54(12): 817–8.
12. Parker JM, Torrington KG, Phillips YY. Sarcoidosis complicated by chylothorax. *South Med J* 1994; 87(8): 860–2.
13. Daniel Salerno MD. Sarcoidosis pleural effusion: A not so common feature of a well known pulmonary disease. *Respiratory Care* 2010; 55(4):478-480.